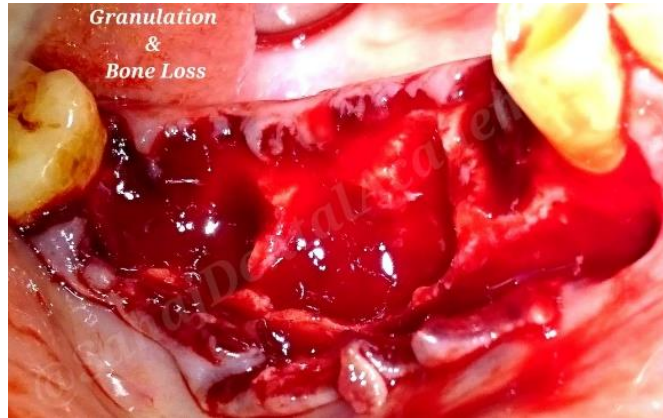
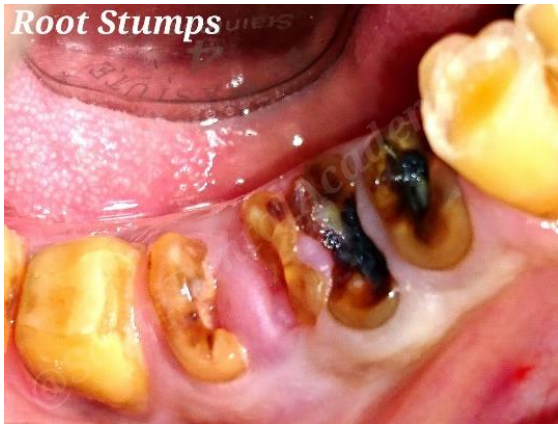
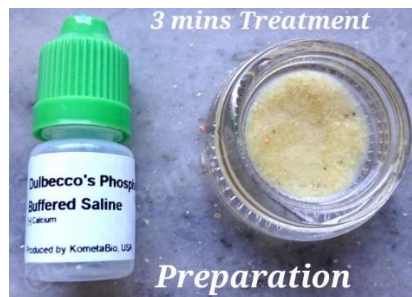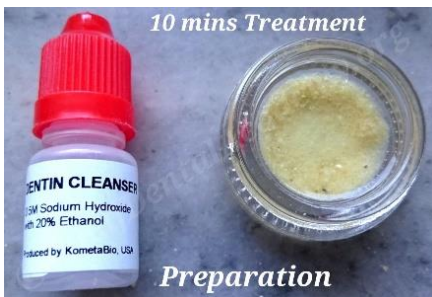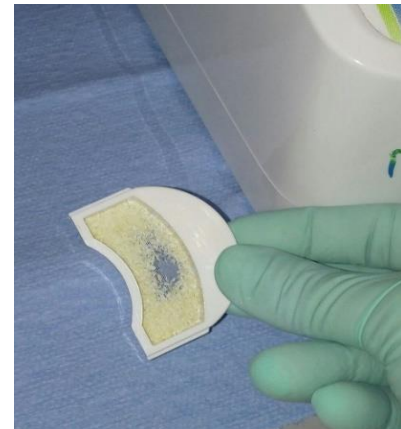
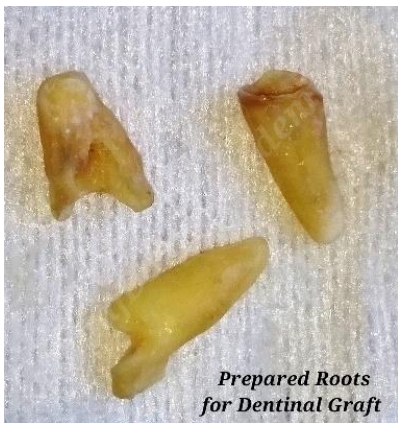# Topic: GBR using the sausage technique and dentin graft

Case by: Dr. Sandeep Singh

Patient presented to our clinic with mobile #29, 30 and 31 (45,46,47 FDI) with only root stumps. Treatment plan included extraction of mobile roots, guided bone regeneration using grafts and membrane placement in the sausage technique for graft immobilization and immediate implant placement with the aim to generate sufficient bone level and ridge height to support implant stability.

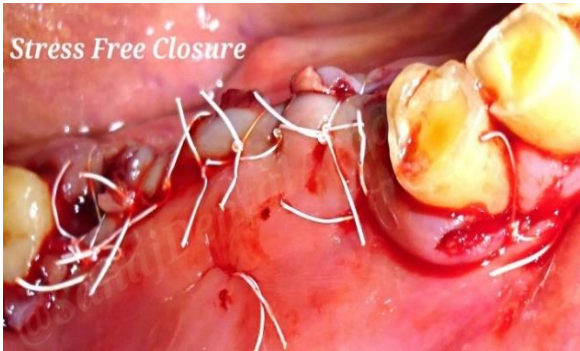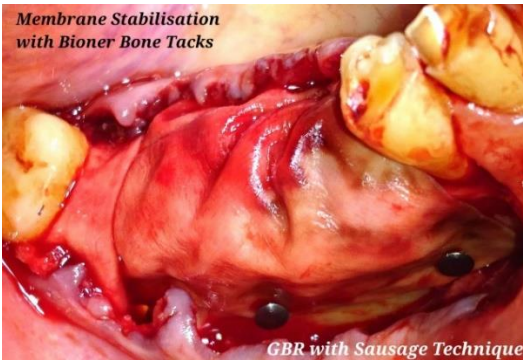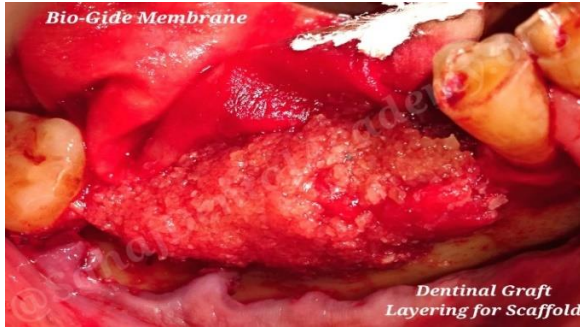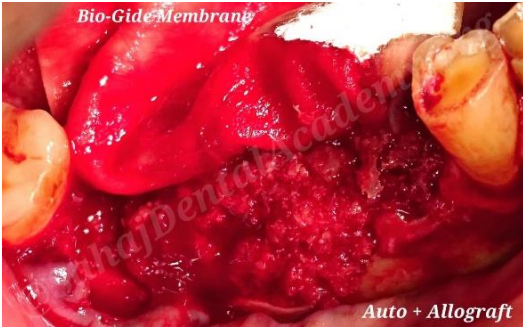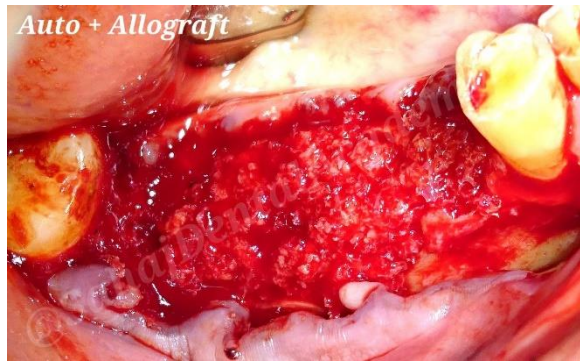


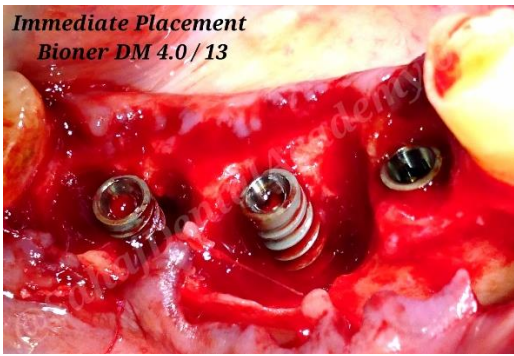Pre-op condition (top left). Extraction and site preparation reveals substantial bone loss and granulation tissue formation (top right). Site cleanup.

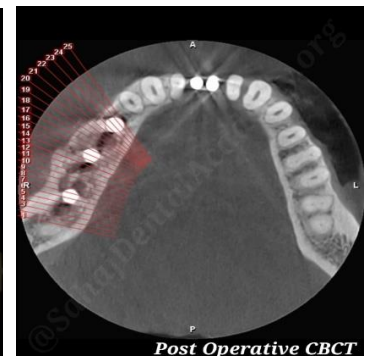
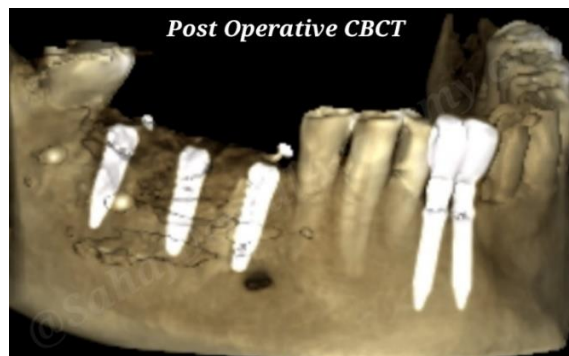
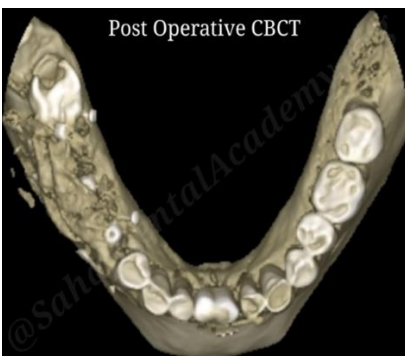


Autologous tooth graft preparation: Mechanical cleaning of extracted root prior to graft preparation. Running the KometaBio Smart Dentin Grinder for 23 seconds. Then treatment of graft with cleanser and wash. In this case we mix the dentin graft with Allograft and site blood for additional volume.





Placement of 3 Bioner DM 4.0 / 13 mm implants followed by placement of the prepared graft mix to cover the implants. Bio-Gide resorbable membrane is then placed over the grafted site and immobilized using Bioner Bone Tacks on both lingual palatal and vestibular side. This type of membrane coverage and fixation is to provide graft stability to assure dimensional integrity during initial healing phase (sausage technique). Stress free flap suturing to complete the surgical procedure.



Post-operative CBCTs.